

CASE REPORT

Late recurrence of a single gland primary hyperparathyroidism—Atypical parathyroid adenoma or misdiagnosed parathyroid carcinoma

Jessica Kotliarevskaia^{1,2}  | Udo Siebolts^{3,4} | Henning Dralle^{5,6} | Frank Schuppert¹

¹Department of Gastroenterology, Endocrinology, Diabetology and General Medicine, Klinikum Kassel, Kassel, Germany

²Department of Gastroenterology and Oncology, Vivantes Klinikum Spandau, Berlin, Germany

³Institute of Pathology, Martin Luther University, Halle, Germany

⁴Germany and Institute of Pathology Cologne University, Cologne, Germany

⁵Department of Surgery, Martin Luther University, Halle, Germany

⁶Department of Endocrine Surgery, University Hospital Essen, Essen, Germany

Correspondence

Jessica Kotliarevskaia, Department of Gastroenterology and Oncology, Vivantes Klinikum Spandau, Neue Bergstraße 6, 13585 Berlin, Germany. Email: jessica.kotliarevskaia@web.de

Key Clinical Message

This case report aims to raise awareness of differential diagnoses of hypercalcemia and primary hyperparathyroidism, including parathyroid carcinoma and atypical adenoma, and to highlight the diagnostic challenges.

Abstract

Parathyroid carcinoma is a rare and often fatal cause of primary hyperparathyroidism and hypercalcemia. To date, there is still no clear-cut diagnostic pathway for parathyroid carcinoma established, which results in major diagnostic ambiguity and complexity. Clinical differentiation between benign parathyroid adenoma and carcinoma is challenging and ultimately the diagnosis remains histopathological. We present a case of a 58-year-old female patient with parathyroid tumor recurrence after parathyroidectomy because of primary hyperparathyroidism. The first tumor was histologically classified as an atypical parathyroid adenoma by a specialized endocrine pathologist. Eleven years after the primary tumor resection a new tumor recurred. Retrospectively, after the tumor recurrence, the primary diagnosis of the atypical adenoma was questioned, and the tumor was temporarily classified to rather be a parathyroid carcinoma. This case aims to raise awareness for the diagnostic challenge of parathyroid carcinomas as a rare cause of primary hyperparathyroidism and therewith to improve treatment and prognosis.

KEYWORDS

atypical parathyroid adenoma, hypercalcemia, parathyroid carcinoma, parathyromatosis, primary hyperparathyroidism

1 | INTRODUCTION

The general prevalence of primary hyperparathyroidism is low, estimated to be less than 1%, but primary

hyperparathyroidism is the most common cause of hypercalcemia.^{1,2}

Most commonly, it is caused by parathyroid adenomas or atypical adenomas (85%), parathyroid hyperplasia

This is an open access article under the terms of the [Creative Commons Attribution-NonCommercial-NoDerivs](https://creativecommons.org/licenses/by-nc-nd/4.0/) License, which permits use and distribution in any medium, provided the original work is properly cited, the use is non-commercial and no modifications or adaptations are made.

© 2024 The Authors. *Clinical Case Reports* published by John Wiley & Sons Ltd.

(10%) and multiple adenomas (4%). Less than 1% of cases are caused by parathyroid carcinomas.^{3,4}

Throughout the years, we treated a patient with a parathyroid tumor in the endocrine outpatient clinic. The patient first presented with an atypical parathyroid adenoma and was later found to have a recurrence of the atypical adenoma, which was temporarily thought to be a parathyroid carcinoma due to diagnostic ambiguity.

2 | CASE PRESENTATION

In 1996 a 32-year-old, otherwise healthy female patient was diagnosed with primary hyperparathyroidism during a routine health check since parathyroid hormone (PTH) serum levels were elevated to 127 ng/L (normal range: 10–65 ng/L) and calcium serum levels were elevated up to 3.6 mmol/L (normal range: 2–2.5 mmol/L) (Figure 1). Other laboratory investigations from 1996 which led to the diagnosis of primary hyperparathyroidism are no longer accessible.

At that time, she did not exhibit any specific symptoms attributable to hypercalcemia. A caudal parathyroid tumor was found on the left side during the neck ultrasound scan, so a subtotal left-sided thyroid lobectomy and caudal parathyroidectomy were performed on June 3, 1996, to surgically remove the supposed benign parathyroid adenoma. Unfortunately, the capsule of the tumor ruptured

intraoperatively. After the operation, the calcium levels returned to normal (Figure 1) and the PTH levels were described in the medical report to be in the normal range. The exact PTH serum levels after the operation in 1996 are no longer available. The histological report showed an atypical, predominately oncocyctic parathyroid adenoma (pictures not shown). No secure signs matching the criteria of parathyroid malignancy, like vascular invasions or breaches through the capsule with invasion of the surrounding soft tissue, were found. Despite that, signs favoring parathyroid carcinomas were seen, including relatively high mitotic figures, a distinct nuclear morphology with prominent nucleoles and fibrous septa emerging from a thick fibrous capsule. Unfortunately, the histopathological material from 1996 is no longer available but the specific information is recorded in the pathology report.

At that time, regardless of the ambiguous pathological findings, this tumor was classified as an atypical parathyroid adenoma. Concluding, regular follow-up of local findings and blood calcium and PTH levels was recommended.

3 | OUTCOME AND FOLLOW-UP

During a routine follow-up appointment in 2007, 11 years after the first presentation, elevated levels of intact PTH of

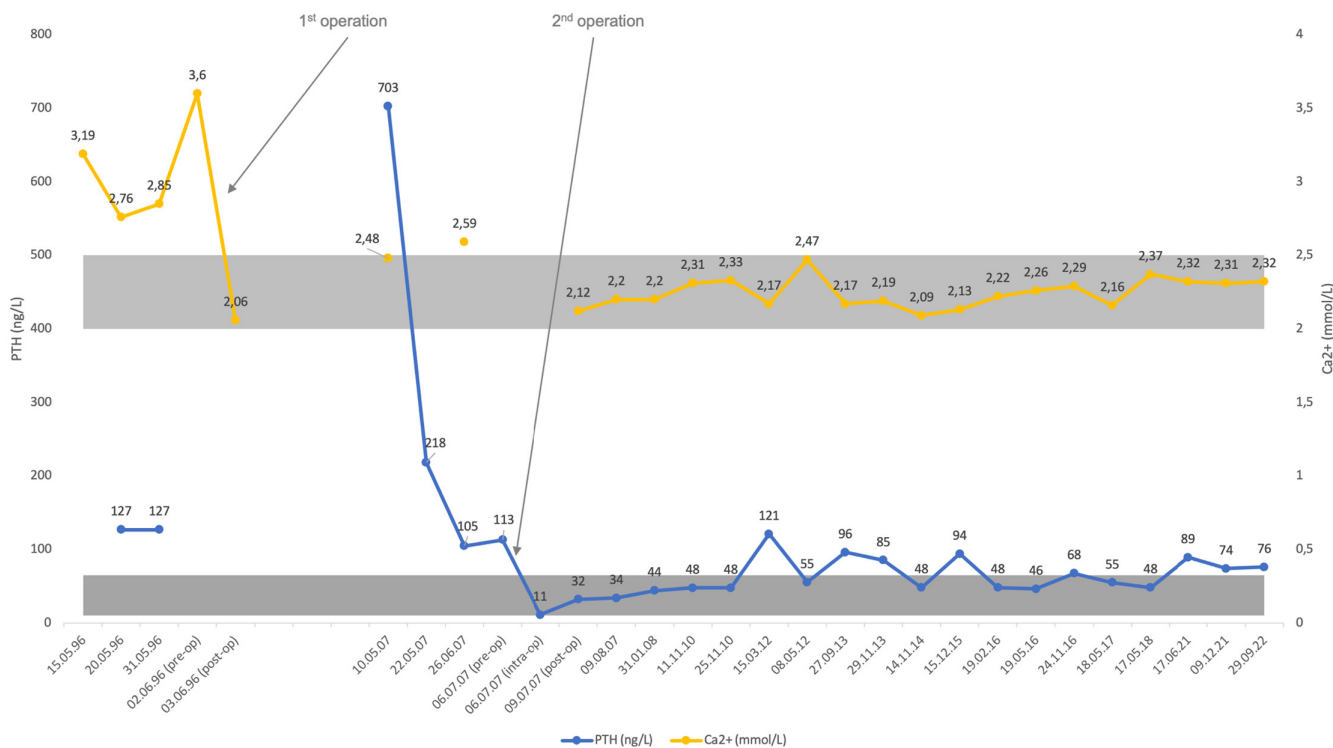


FIGURE 1 This figure depicts serum levels of parathyroid hormone (PTH) and calcium (Ca²⁺) throughout the course of the disease in this patient covering 26 years of follow-up. The normal range of serum PTH levels is up to 65 ng/L and the normal range of serum calcium is between 2 and 2.5 mmol/L. Normal ranges for both parameters are indicated by the gray area.

703 ng/L were found. A control 2 weeks later still showed elevated levels of 218 ng/L. This difference in PTH values was explained at that time by PTH being secreted in a pulsatile manner.⁵ The calcium levels were in the upper normal range at 2.48 mmol/L (normal range: 2–2.5 mmol/L). Three weeks later another laboratory control was performed showing elevated levels of intact PTH of 104.6 ng/L and elevated calcium levels of 2.59 mmol/L. Additionally, the 25-OH vitamin D3 level was low at 7.1 ng/mL which was explained to be the result of decreased intake and reduced sun exposure due to a lack of clinical symptoms (Table 1).

A magnetic resonance imaging (MRI) of the neck was performed showing a 5 mm left-sided para-tracheal soft tissue tumor. At that point, the suspicion arose that the initial tumor that was classified as an atypical adenoma might have been misdiagnosed. Because the initial tumor showed features of parathyroid carcinoma and the patient now presented with a tumor recurrence, she was suspected to have a parathyroid carcinoma recurrence.

A Tc-99m sestamibi scintigraphy was performed and showed a well-defined left-sided activity enhancement corresponding to the tumor detected in the MRI scan. No evidence of distant metastases or suspicious lymph nodes was found. Subsequently, a neck sonography was performed showing an inhomogeneous hypoechoic polycystic defined area measuring 17x10 mm which was clearly extra-thyroidal and distinctly located caudally to the small residual of the left thyroid gland.

The patient was referred to an endocrine surgical center in Halle, Germany for the ensuing operation. On July 6, 2007, at the age of 43, she received an en-bloc resection of the tumor recurrence measuring 12 mm. The tumor was in very close proximity to the left recurrent laryngeal nerve, but the function could be preserved during the operation (Figure 2A–C). The titling of the intra-operative photographic documentation demonstrates the assumption of a parathyroid carcinoma recurrence at that point. The

intraoperative PTH was initially 113 ng/L and normalized to 11.1 ng/L after resection (Figure 1). Pathological findings suggested a parathyroid carcinoma including trabecular and diffuse growth pattern distinctly different compared to normal parathyroid tissue (Figure 3C,F–H), tumor cell pleomorphism with macronucleoli (Figure 3D), mitotic figures (up to three mitoses per one high power field, 52 mitoses per 50 high power fields) and a proliferation index (Ki-67) of up to 10%, tumor necrosis (Figure 3A,D,G) and tumor infiltration into surrounding soft tissue and striated muscle (Figure 3B,E).

Thus, the tumor met certain WHO criteria for malignancy because of (a) macronucleoli, (b) more than five mitoses per 50 high power fields and (c) tumor necrosis. However, no clear-cut diagnosis could be made due to the lack of decisive criteria like vascular invasion neither by conventional staining like hematoxylin and eosin (H&E) and Elastica van Gieson (EvG) staining nor by immunohistochemistry (CD31).

The resection borders and the lymph nodes were free from tumor. After surgery, calcium levels normalized. Still, the patient developed slight symptoms like irritability, muscle cramps and fatigue which were attributed to symptoms of hypocalcemia; hence oral substitution was started and discontinued after several weeks.

During all follow-up appointments over the subsequent years, the last one being held in September 2022 at the age of 58, the patient was feeling well and PTH as well as serum calcium levels were in normal ranges without any oral calcium supplementation. Due to 25-hydroxy vitamin D levels being low on follow-up with 14.6 ng/mL (normal range: 20–50 ng/mL) (Table 2), the patient receives to date 1000 units of 25-hydroxy vitamin D orally once a day to ensure optimal vitamin D3 status.

Retrospectively, this patient was classified to have a recurrence of the atypical parathyroid adenoma, because only some, but not all, histopathological findings were indicative of parathyroid carcinoma.

TABLE 1 Data from 26.06.07 when recurrence of primary hyperparathyroidism was diagnosed.

Laboratory marker	Measurement result	Normal range
Intact PTH	104.6 ng/L	10–65 ng/L
PTH-related peptide	< 1.5 pmol/L	<1.5 pmol/L
Total serum calcium	2.59 mmol/L	2–2.5 mmol/L
Ionized serum calcium	1.36 mmol/L	1.17–1.29 mmol/L
Urinary calcium	8.1 mmol/24 h	<6.20 mmol/24 h
Serum phosphate	0.64 mmol/L	0.84–1.45 mmol/L
25 OH vitamin D3	7.1 ng/mL	20–50 ng/mL
Alkaline phosphatase	113 U/L	40–140 U/L
Bone alkaline phosphatase	8.9 µg/L	4.9–22.7 µg/L
Osteocalcin	18.0 µg/L	15–46 µg/L
N-telopeptide	5.9 nmol/L	6.2–19 nmol/L

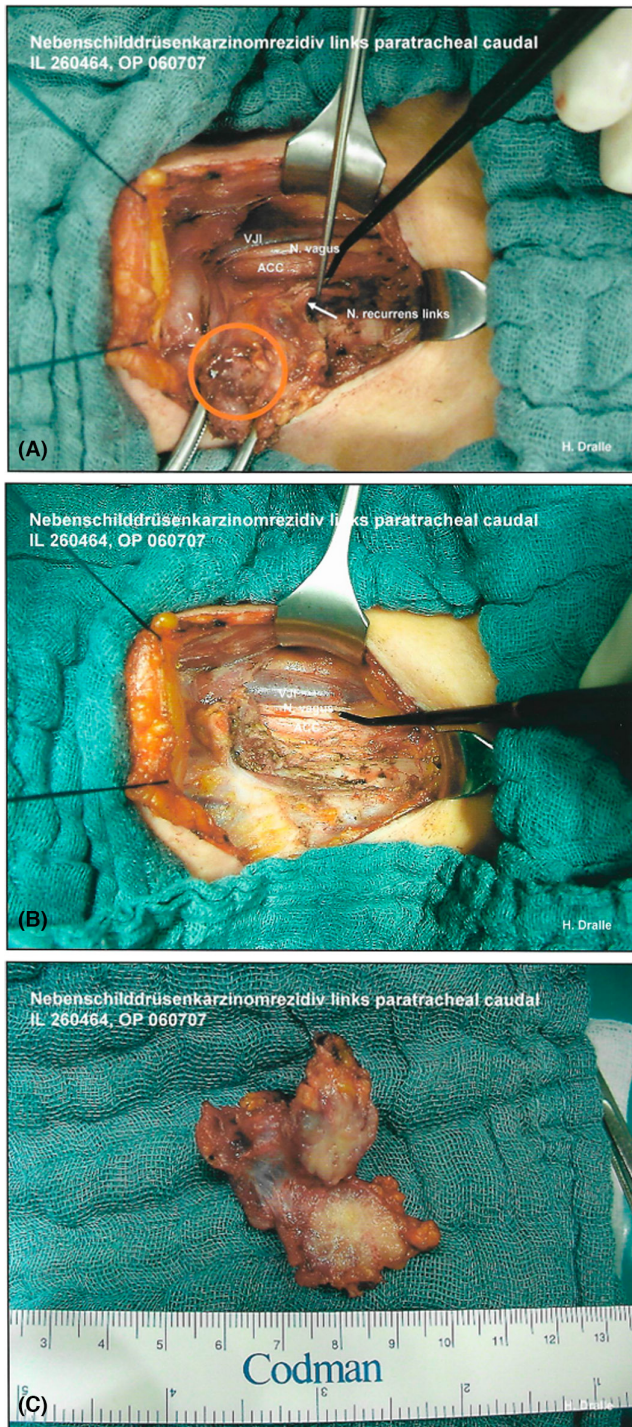


FIGURE 2 (A, B) Demonstrating the intra-operative situs of the suspected parathyroid carcinoma with close proximity to the left recurrence nerve and (C) the explanted tumor.

4 | DISCUSSION

This case report shows the course of a female patient with an atypical parathyroid adenoma recurrence after initial surgical resection. The follow-up comprises a period of 26 years so far, starting with the primary operation. In the

last 15 years, during the follow-up after the second operation, no further tumor recurred to date.

Furthermore, this case highlights the difficulties in diagnosing a parathyroid carcinoma since the tumor being resected during the second operation in 2007 was initially classified as a parathyroid carcinoma. Retrospectively, over the course of this case report being issued, the tumor was classified to rather be an atypical parathyroid adenoma recurrence because of a lack of distant metastases and vascular invasion.

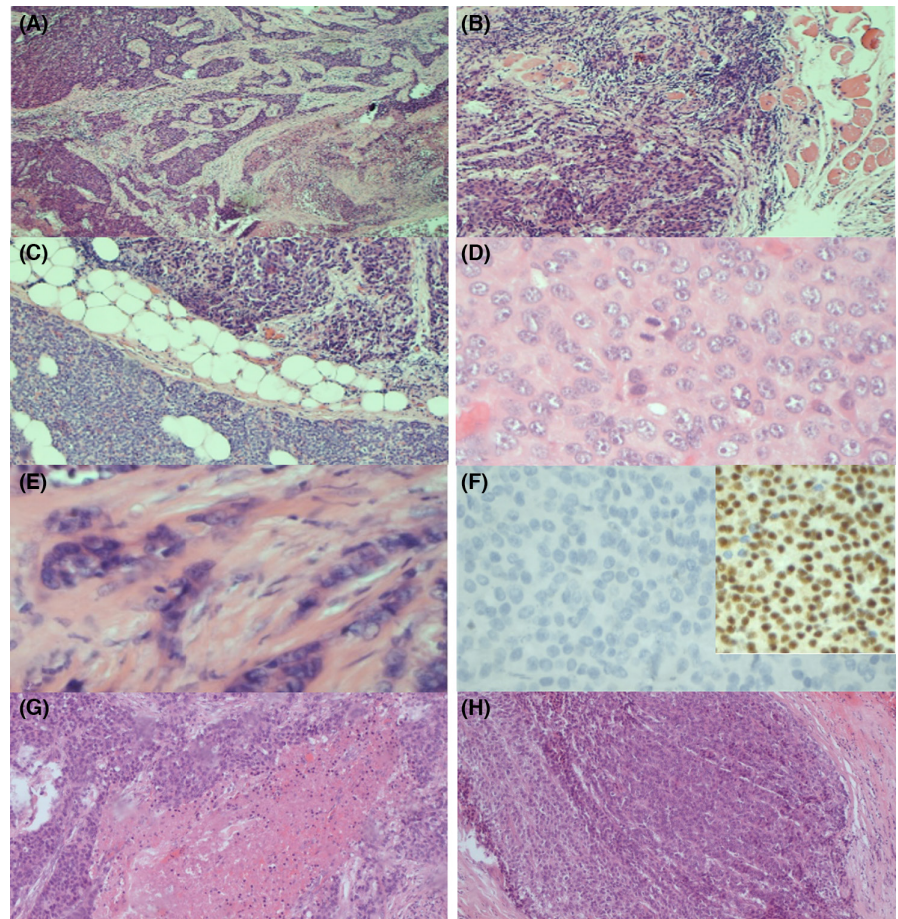
Hence, a greater level of suspicion of malignancy is required to optimize patient care and to achieve a favorable long-term outcome. Often, the diagnosis is made in retrospect after a recurrence of hypercalcemia or hyperparathyroidism either due to local tumor spread or distant metastases.^{1,3,6–8}

Parathyroid carcinoma is difficult to differentiate from atypical parathyroid adenomas before surgical intervention. However, this case demonstrated the complexity of differentiating atypical parathyroid adenoma from parathyroid carcinoma, even after surgery.

Clinical signs and symptoms of hypercalcemia are often subtle if present at all. Leading biochemical markers in parathyroid carcinoma include calcium levels >3 mmol/L (normal range: 2–2.5 mmol/L) and PTH elevations of greater than 2–3 times the normal range (normal range: 10–65 ng/L).^{3,4,6,8–12} In clinical practice, calcium levels of >4 mmol/L and PTH >1000 ng/L are often seen in patients with parathyroid carcinoma. In this patient, the PTH was found to be in the range of 703 ng/L only once on follow-up with a drop to 218 ng/L only 2 weeks later. This drop could be explained both by the pulsatile secretion of PTH and by a vitamin D deficiency since the 25-OH vitamin D3 level was 7.1 ug/L at that time (normal range: 20–50 ng/mL) (Table 1). Other factors that might have affected the PTH levels are dehydration, chronic kidney injury or bisphosphonate intake. None of these factors were documented on the medical record. Regardless of that variation, the repeated laboratory findings of PTH and calcium in this patient are empirically too low to be indicative of parathyroid carcinoma.

Additionally, parathyromatosis and four-gland hyperplasia should be considered a differential diagnosis. Four gland hyperplasia was ruled out in this patient by neck imaging. Parathyromatosis is a rare cause of recurrent hyperparathyroidism, in which several nodules of hyperfunctioning parathyroid tissue form in the neck or mediastinum. Usually, parathyromatosis presents as small and numerous nodules whereby there is no real fibrous capsule present like in parathyroid adenoma or parathyroid carcinoma.¹³ Hence, the mitotic activity, histomorphological growth, tumor necrosis, presence of a solitary nodule

FIGURE 3 Various pictures of the atypical parathyroid adenoma from the second operation in July 2007. (A) H&E stain (50 times) desmoplastic stroma reaction induced by the tumor and focal necrosis (B) H&E stain (100 times) invasion of soft tissue and striated muscle (C) H&E stain (100 times) dysplastic tumor adjacent to normal parathyroid tissue (D) H&E stain (400 times) detail magnification of dysplastic tumor cells revealing prominent nucleoli and mitosis (E) H&E stain (400 times) detail magnification of cord-like infiltrating tumor cells with desmoplastic stroma reaction (F) Immunohistochemistry for parafibromin (200 times) of tumor cells (negative) and for normal parathyroid tissue (positive). Tumor necrosis (G) and trabecular growth (H) are also shown.



and the fibrous capsule in this patient ruled out parathyromatosis. In addition, parathyromatosis does not typically infiltrate the surrounding soft tissues and striated muscle as shown in [Figure 3B](#).¹³

No clear-cut diagnostic workup has been established so far, making the diagnosis of parathyroid carcinoma very challenging. The American Joint Committee of Cancer (AJCC) proposed a classification system for parathyroid cancer using the TNM classification of malignant tumors. Nevertheless, there is limited data on tumor characteristics and associated prognosis, so no prognostic stages can be concluded from this staging system so far.^{12,14}

After surgical excision of the tumor, diagnosis of malignancy can be aided by distinct histological findings, as numerous studies showed. These include mitotic figures, trabeculated parenchyma including thick fibrous bands and capsular or vascular invasion ([Figure 3](#)). Most importantly, vascular invasion should lead to the suspicion of malignancy.¹⁵ Additionally, in contrast to benign parathyroid tissue seeding like in parathyromatosis, real lymph node or distant metastases are the biological evidence of malignancy.^{3,4,7,10,13,16} In this case, neither the presence of abnormal mitosis nor the thick fibrous bands initially led to critical clinical judgment and suspicion of malignancy after the first operation

in 1996, even though it is doubtful whether the disease course in this particular patient would have changed significantly.

Recurrence of a parathyroid tumor should always be reflected critically. Parathyroid carcinoma has a high tendency of recurrence after surgical excision, affecting 25%–80% of patients. The mean time to recurrence is 3 years but can range from 1 to 20 years after the initial surgery. A cure is unlikely once a malignant tumor has recurred, but prolonged survival is common.^{8–11,17}

Benign hyperparathyroidism is generally not considered to be a precancerous condition for the development of parathyroid carcinoma. In contrast, atypical parathyroid adenomas are classified to exhibit some features of parathyroid carcinoma but lack unequivocal features like invasive growth. Thus, atypical parathyroid adenomas are classified to have an uncertain malignant potential.^{1,8,10,14,18}

The single most effective therapy for parathyroid carcinoma is complete surgical resection. En-bloc resection should be performed at the time of the first presentation as this reduces the rate of capsule injury and cell seeding concurrently. In clinical practice, only about 12% of parathyroid carcinoma cases are en-bloc excised at first presentation.^{1,3,4,6,8,9,11,19}

TABLE 2 Serum 25-OH vitamin D3 levels during follow-up after tumor recurrence which was surgically removed on July 6, 2007. Normal range 20–50 ng/mL.

Date	Serum 25-OH vitamin D3 (ng/ml)
26.06.07	7.1
15.03.12	14.6
15.12.15	7.25
19.02.16	44
19.05.16	24.6
24.11.16	41
18.05.17	41.9
17.06.21	35.3
09.12.21	42.7
29.09.22	29.8

Due to these properties, close follow-up and monitoring after excision are crucial. Life-long follow-up is necessary since the development of metastases has been documented up to 20 years after initial diagnosis.^{6,8,9,11,17}

In the literature, several parathyroid carcinoma cases were reported which were originally diagnosed as benign parathyroid adenoma highlighting the diagnostic indistinctness. Parathyroid carcinoma is often diagnosed retrospectively at a late disease stage, frequently with the presence of distant metastasis.^{17,20,21}

There are no existing guidelines on follow-up regimes for atypical parathyroid adenomas. In this case, the first follow-up took place every 6 months. After a few years without another tumor recurrence the follow-up interval was prolonged to 1 year and is planned to be continued in this manner.

The first line treatment for suspected typical or atypical parathyroid adenomas is surgical removal, congruently to the treatment approach in parathyroid carcinomas. If a patient with any type of parathyroid tumor is unable to undergo surgery, the primary treatment approach consists of drug therapy to control hypercalcemia and accompanying symptoms.²²

Atypical parathyroid adenomas have the potential to recur, even when removed completely. The overall recurrence rate of atypical parathyroid adenomas after surgical removal is 3%.²³ There have been no studies conducted on the recurrence rate of atypical parathyroid adenomas after capsular rupture during surgery so far. Therefore, no conclusion can be drawn about the exact effect of capsular rupture on tumor recurrence. In this patient, it is most likely that tumor recurrence has been facilitated due to the capsular rupture either by cell seeding or incomplete removal of the tumor after the rupture.

To summarize, this case should raise awareness for differential diagnosis of hypercalcemia and primary

hyperparathyroidism. Biochemical markers and imaging modalities can aid the diagnosis of parathyroid carcinoma, but ultimately the diagnosis remains histopathological. Because of the overlap in histopathological findings, the distinction between parathyroid carcinoma and atypical parathyroid adenoma is challenging. Thick fibrous capsules, capsular invasion and necrosis can also be present in atypical adenomas, even though they are rarely found. This should raise a high level of suspicion for malignancy. In the future, additional molecular markers might enable distinct diagnosis.^{1–3,6,8,11,24}

AUTHOR CONTRIBUTIONS

Jessica Kotliarevskaia: Conceptualization; data curation; formal analysis; investigation; writing – original draft. **Udo Siebolts:** Data curation; writing – review and editing. **Henning Dralle:** Data curation; writing – review and editing. **Frank Schuppert:** Conceptualization; data curation; project administration; supervision; writing – review and editing.

FUNDING INFORMATION

No public or commercial funding.

CONFLICT OF INTEREST STATEMENT

None declared.

DATA AVAILABILITY STATEMENT

Original data generated and analyzed during this study are included in this published article.

ETHICS STATEMENT

Not applicable.

CONSENT

Written informed consent was obtained from the patient to publish this report in accordance with the journal's patient consent policy.

ORCID

Jessica Kotliarevskaia  <https://orcid.org/0000-0001-8243-7043>

REFERENCES

- Alperstein A, Bhayani R. Parathyroid carcinoma, a rare cause of primary hyperparathyroidism. *Case Reports*. 2014. doi:10.1136/bcr-2014-204279
- Fernandez-Ranvier GG, Khanafshar E, Jensen K, et al. Parathyroid carcinoma, atypical parathyroid adenoma, or parathyromatosis? *Cancer*. 2007;110(2):255-264. doi:10.1002/cncr.22790
- Talat N, Schulte KM. Clinical presentation, staging and long-term evolution of parathyroid cancer. *Ann Surg Oncol*. 2010;17(8):2156-2174. doi:10.1245/s10434-010-1003-6

4. Carlson D. Parathyroid pathology: hyperparathyroidism and parathyroid tumors. *Arch Pathol Lab Med.* 2010;134(11):1639-1644. doi:10.5858/2009-0578-ccr.1
5. Harms H, Kaptaina U, Külpmann T, Hesch RD. Pulse amplitude and frequency modulation of parathyroid hormone secretion in man. *Acta Endocrinol.* 1988;117(4):S171. doi:10.1530/acta.0.117s171
6. Harari A, Waring A, Fernandez-Ranvier G, et al. Parathyroid carcinoma: a 43-year outcome and survival analysis. *J Clin Endocrinol Metab.* 2011;96(12):3679-3686. doi:10.1210/jc.2011-1571
7. Lenschow C, Schrägle S, Kircher S, et al. Clinical presentation, treatment, and outcome of parathyroid carcinoma. *Ann Surg.* 2020;275(2):e479-e487. doi:10.1097/sla.0000000000004144
8. Shane E. Parathyroid carcinoma. *J Clin Endocrinol Metabol.* 2001;86(2):485-493. doi:10.1210/jcem.86.2.7207
9. Kebebew E. Localization and reoperation results for persistent and recurrent parathyroid carcinoma. *Arch Surg.* 2001;136(8):878. doi:10.1001/archsurg.136.8.878
10. Schantz A, Castleman B. Parathyroid carcinoma. A study of 70 cases. *Cancer.* 1973;31(3):600-605.
11. Sharretts JM, Kebebew E, Simonds WF. Parathyroid cancer. *Semin Oncol.* 2010;37(6):580-590. doi:10.1053/j.seminoncol.2010.10.013
12. Chu YH, Lloyd RV. Parathyroid cancer: pathology and genetics. Reference module in biomedical sciences. 2018. doi:10.1016/b978-0-12-801238-3.65088-2
13. Aksoy-Altinboga A, Akder Sari A, Rezanko T, Hacıyanlı M, Orgen CA. Parathyromatosis: critical diagnosis regarding surgery and pathologic evaluation. *Korean J Pathol.* 2012;46(2):197-200. doi:10.4132/koreanjpathol.2012.46.2.197
14. AJCC CANCER STAGING MANUAL Seventh Edition. https://www.facs.org/media/j30havvyf/ajcc_7thed_cancer_staging_manual.pdf
15. Erickson LA, Mete O, Juhlin CC, Perren A, Gill AJ. Overview of the 2022 WHO classification of parathyroid tumors. *Endocr Pathol.* 2022;33(1):64-89. doi:10.1007/s12022-022-09709-1
16. Schulte KM, Gill AJ, Barczynski M, et al. Classification of parathyroid cancer. *Ann Surg Oncol.* 2012;19(8):2620-2628. doi:10.1245/s10434-012-2306-6
17. Ellis HA, Floyd M, Herbert FK. Recurrent hyperparathyroidism due to parathyroid carcinoma. *J Clin Pathol.* 1971;24(7):596-604. doi:10.1136/jcp.24.7.596
18. Galani A, Morandi R, Dimko M, et al. Atypical parathyroid adenoma: clinical and anatomical pathologic features. *World J Surg Oncol.* 2021;19(1). doi:10.1186/s12957-021-02123-7
19. Machens A, Lorenz K, Dralle H. Parathyroid hormone levels predict long-term outcome after operative Management of Parathyroid Cancer. *Horm Metab Res.* 2017;49(7):485-492. doi:10.1055/s-0043-109562
20. Grayzel EF. Hyperparathyroidism in a patient with parathyroid carcinoma. *Arch Intern Med.* 1967;120(3):349. doi:10.1001/archinte.1967.00300030091018
21. Ebner S, Emerson CH. Documentation of parathyroid carcinoma fifteen years after resection of a parathyroid "adenoma." *Clin Endocrinol (Oxf).* 1993;38(6):659-661. doi:10.1111/j.1365-2265.1993.tb02151.x
22. El-Hajj FG. Parathyroid carcinoma. In: UpToDate, Post T (Ed), Wolters Kluwer, 2021. Accessed November 14, 2023. www.uptodate.com
23. Cetani F, Marcocci C, Torregrossa L, Pardi E. Atypical parathyroid adenomas: challenging lesions in the differential diagnosis of endocrine tumors. *Endocr Relat Cancer.* 2019;26(7):R441-R464. doi:10.1530/ERC-19-0135
24. Schulte JJ, Pease G, Taxy JB, Hall C, Cipriani NA. Distinguishing Parathyromatosis, atypical parathyroid adenomas, and parathyroid carcinomas utilizing histologic and clinical features. *Head Neck Pathol.* 2021;15(3):727-736. doi:10.1007/s12105-020-01281-6

How to cite this article: Kotliarevskaja J, Siebolts U, Dralle H, Schuppert F. Late recurrence of a single gland primary hyperparathyroidism—Atypical parathyroid adenoma or misdiagnosed parathyroid carcinoma. *Clin Case Rep.* 2024;12:e8440. doi:10.1002/ccr.8440