


## CASE STUDY

**CSF Neurofilament light chain level predicts axonal damage in cerebral vasculitis**Marc Pawlitzki<sup>1,2,\*</sup> , Michaela Butryn<sup>1,\*</sup>, Florian Kirchner<sup>3</sup>, Jacqueline Färber<sup>4</sup>, Oliver Beuing<sup>5</sup>, Jens Minnerup<sup>2</sup>, Sven G. Meuth<sup>2</sup> & Jens Neumann<sup>1</sup><sup>1</sup>Department of Neurology, Otto-von-Guericke University, Leipziger Straße 44, 39120 Magdeburg, Germany<sup>2</sup>Department of Neurology with Institute of Translational Neurology, Albert-Schweitzer-Campus 1, 48149 Münster, Germany<sup>3</sup>Department of Neurology, AMEOS Klinikum Bernburg, Kustrenaer Str. 98, 06406 Bernburg, Germany<sup>4</sup>Institute of Medical Microbiology, Infection Control and Prevention, Otto-von-Guericke University, Leipziger Straße 44, 39120 Magdeburg, Germany<sup>5</sup>Department of Neuroradiology, Otto-von-Guericke University, Leipziger Straße 44, 39120 Magdeburg, Germany**Correspondence**

Marc Pawlitzki, Department of Neurology, Otto-von-Guericke University, Leipziger Straße 44, 39120 Magdeburg. Tel: + 49 391 6713431; Fax: + 49 391 6715233; E-mail: marc.pawlitzki@med.ovgu.de

**Funding information**

No funding information provided.

Received: 19 February 2019; Revised: 28 March 2019; Accepted: 10 April 2019

*Annals of Clinical and Translational Neurology* 2019; 6(6): 1134–1137

doi: 10.1002/acn3.790

\*Both authors contributed equally to this work.

**Introduction**

Primary angiitis of the central nervous system (PACNS) is rare, poorly understood and challenging to diagnose with currently available noninvasive diagnostics.<sup>1</sup> Conventional arterial angiography is a sensitive method for diagnosing PACNS, even in the absence of a histological analysis, but can turn out to be inconclusive in some cases.<sup>2</sup>

Elevated levels of neurofilament light chain (NFL) in sera or in the cerebrospinal fluid (CSF) represent neuroaxonal damage and are proposed to have a predictive value concerning outcomes in patients suffering from inflammatory, neurodegenerative, and cerebrovascular diseases.<sup>3–6</sup>

**Abstract**

The rarity of primary angiitis of the central nervous system (PACNS) demands diagnostic and prognostic biomarkers. We retrospectively measured Neurofilament light chain (NFL) concentrations in cerebrospinal fluid in a severely relapsing PACNS patient at multiple time points during the course of the disease. A marked increase in NFL levels preceding the onset of neuro-axonal damage and arterial-vessel abnormalities was observed with magnetic resonance imaging as well as with MR- and conventional angiography. Thus, marked elevation of NFL in PACNS seems to occur ahead of definitive radiological abnormalities and might serve as a diagnostic biomarker.

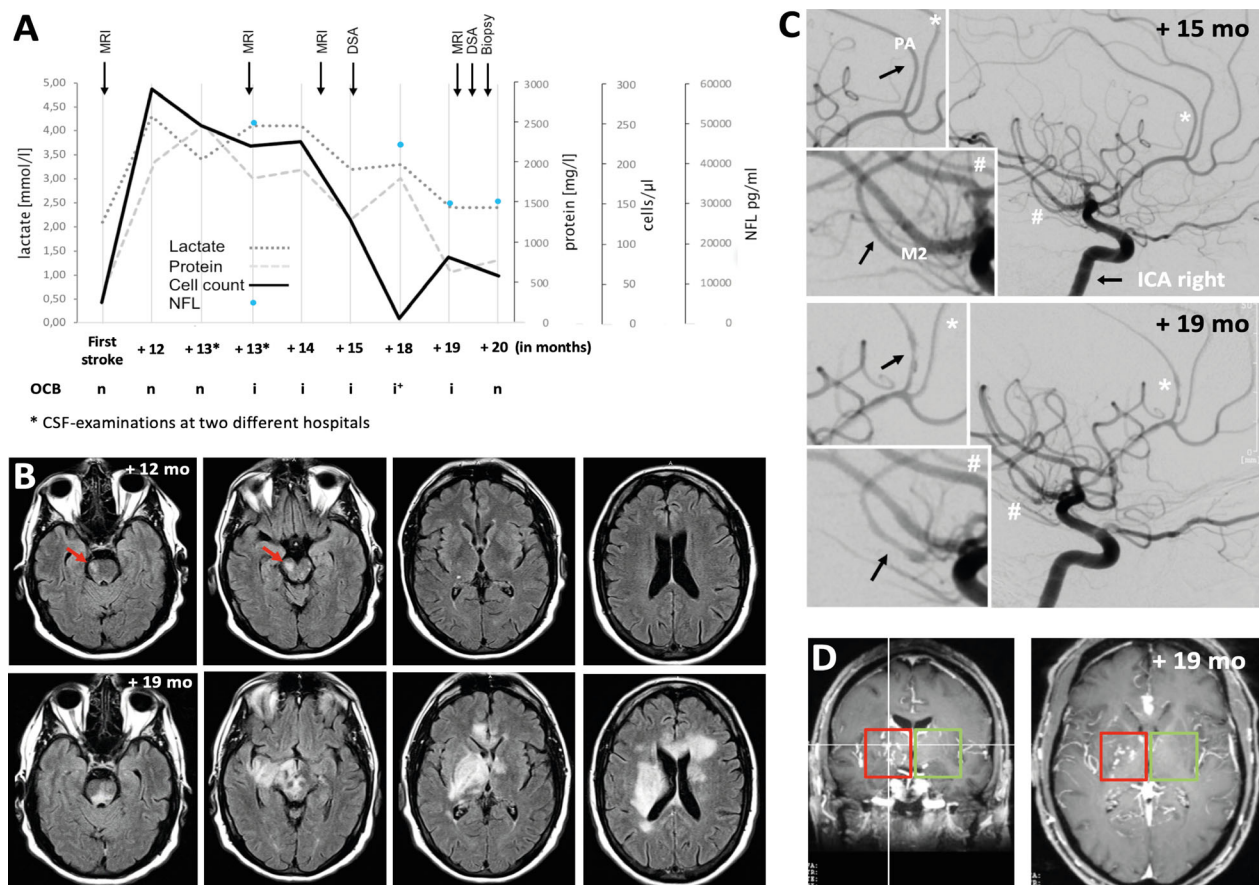
Here we present a case of PACNS with normal initial clinical and radiological measurements (including conventional arterial angiography) but with an inflammatory CSF revealing highly elevated CSF-NFL concentrations – which were discovered months before arterial-vessel involvement with pronounced parenchymal injury and severe neurological impairment were observed.

**Case Report**

A 44-year-old Caucasian male without known medical history was diagnosed with two events of stroke (07/2016 and 07/2017) corresponding to small ischemic lesions (9.0 × 6.6 mm and 9.4 × 7.9 mm) within the brainstem (Fig. 1B). The cardiac and MRI/MR-angiography examinations and

the serum markers for generalized vasculitis were normal (Supplemental Text 1). CSF measurements repeatedly revealed a pleocytosis without oligoclonal bands, and microbiological analyses were unremarkable (Fig. 1A, Supplemental Text 1). Intravenous Acyclovir ( $3 \times 750$  mg/day), sulbactam/ampicillin ( $3 \times 3$  g/day), and ceftriaxone (2 g/day) were initially administered and treatment was continued for 14 days. Follow-up examinations in 09/2017 and 11/2017 showed similar CSF results, again without serological or new radiological abnormalities, while the patient remained clinically stable (National Institutes of Health Stroke Scale [NIHSS] = 2 points). The anti-infective therapy was repeated. To exclude a causally related postinfective vasculitis, conventional angiography (11/2017) was initiated but did not reveal any evidence of vasculitis of medium or large vessels (Fig. 1C).

In 02/2018, the patient developed a subacute left-sided moderate hemiparesis, diplopia, a severe dysarthria, and a substantial cognitive decline. MRI examination revealed multiple, bilateral subcortical infarctions, and tumor-like mass lesions in the midbrain and brainstem with partial gadolinium (Gd) enhancement (Fig. 1B). Methylprednisolone (1 g/day for 5 days) was administered intravenously with only slight clinical improvement. At this point in time, the MR- and the conventional angiography displayed characteristic patterns for vasculitis<sup>2</sup> (Fig. 1C and D); CSF and serological parameters remained unchanged. Leptomeningeal and parenchymatous biopsies (03/2018) were performed stereotactically and showed results consistent with a vasculitis. PACNS was diagnosed and another intravenous treatment with methylprednisolone (500 mg/day for 3 days) and 1 g cyclophosphamide (CYP) was



**Figure 1.** (A) Chart shows the course of cell count, concentrations of protein, lactate, neurofilament light protein (NFL) as well as the occurrence of oligoclonal bands (OCB) in the CSF over time (n = no OCB detectable, i = identical OCB in serum and CSF, i+ = identical OCB plus OCB in the CSF). Arrows indicate time points of additive diagnostic (MRI, DSA, biopsy). (B) Panel displays MRI (T2-FLAIR) examinations at two different time points. Red arrows mark first detected T2-hyperintensities. (C) Pictures show digital subtraction angiographies (DSA) at different time points. Black arrows indicate regular arteries (PA = pericallosal artery, M2 = branch of the middle cerebral artery) in 10/2017 and narrowed arteries in 02/2018. (D) Panel presents coronal and axial layers of postcontrast three-dimensional (3D)-T1 with contrast-enhanced lenticulostriate arteries right-sides (red box) in comparison with the left side (green box).

initiated in 03/2018. One month later, MRI examinations revealed persisting Gd enhancement near the lenticulostriate and cerebellar arteries. Another high dose of methylprednisolone (1 g/d for 3 days) and CYP (1 g) was administered. In 05/2018, MRI abnormalities (T2 hyperintensities/Gd enhancement) declined and the patient remained clinically stable. Due to the subacute progressive clinical decline shortly after the last diagnosis without abnormal findings, we retrospectively measured CSF-NFL levels (ELISA kits: UmanDiagnostics NF-light®) and could verify sustained, highly increased NFL levels (since 09/2017) compared to nonvasculitic stroke patients (Fig. 2) and in the absence of clinical and radiological signs of axonal injury (Fig. 1A).

## Discussion

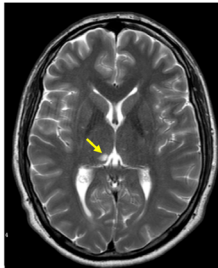

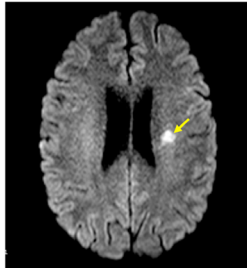
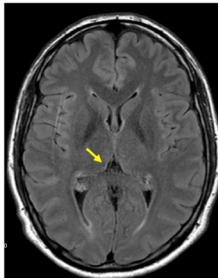
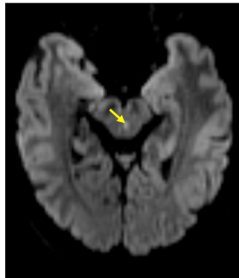

Owing to the aggressive disease course of cerebral vasculitis,<sup>2</sup> our case was extensively assessed including radiological, serological, and CSF analysis. However, except for the increased CSF cell count, there was no initial evidence for PACNS or systemic vasculitis<sup>7,8</sup> and thus immunosuppressive treatment was not started. Previous reports also described relapsing courses of PACNS, but showed clinically silent MRI pathologies and abnormal angiographies<sup>9</sup> which in turn led to early immunosuppressive treatment.<sup>2</sup>

Here, the latency between highly increased CSF-NFL levels and the first indicative changes in the MRI and

conventional angiography was remarkable. CSF-NFL measurements have recently been discovered to possess biomarker qualities in motor neuron<sup>4</sup> and autoimmune diseases,<sup>4,5</sup> reflecting disease activity and clinical outcome even in early (pre)clinical disease stages.<sup>4</sup> Compared to ischemic lesions caused by other etiologies (embolic, microangiopathic) our patient demonstrated highly increased levels of CSF-NFL. In our small cohort of age-matched controls with minor stroke (with comparable NIHSS) and with normal CSF parameters we measured CSF-NFL levels of ~ 1000 pg/mL compared to > 40.000 pg/mL in our index-patient (Fig. 2). Even for events of major stroke CSF-NFL levels are not described in that dimension,<sup>10</sup> nor were these levels reached in our previous study of neurodegenerative and chronic inflammatory diseases.<sup>11</sup>

It is tempting to speculate whether the high CSF cell count in combination with two past cerebrovascular events in the absence of clinical and radiological pathologies, including conventional angiography, should already have led to the initiation of an immunosuppressive treatment.<sup>1</sup> Physicians need to keep in mind that the highly increased CSF cell count seems to be a rare case in PACNS.<sup>7,9</sup> Thus, a multistep diagnostic approach is essential to prevent initially incorrect or delayed treatment.<sup>7</sup>

To summarize, our case implies that NFL level analysis might be one piece of the puzzle to overcome the diagnostic dilemma of inflammatory CSF in the absence of other

	Patient 1	Patient 2	Patient 3		Patient 1	Patient 2	Patient 3
Age at lumbar puncture (years)	39	44	45				
Sex	male	male	male				
NIHSS	0	1	2				
Lesion size	6.5 x 4.5 mm	5.6 x 3.7 mm	9 x 7.2 mm				
CSF Cell count /µl	1	3	0				
CSF protein (mg/dl)	344	490	432				
CSF-NFL (pg/ml)	1046	873	716				

**Figure 2.** Clinical and cerebrospinal fluid values of three age- and sex-matched stroke patients. The first patient presented ischemic thalamic lesion, the second a mesencephalon infarction, and the third an infarction in the territory of the middle cerebral artery. CSF = cerebrospinal fluid, NIHSS = NIH stroke scale, NFL = Neurofilament light chain

pathological findings, as it is a more reliable and faster tool than MRI or conventional angiography for detecting abnormalities and indicating axonal injury in PACNS. However, future studies with larger samples are required to evaluate the biomarker quality of NFL in PACNS.

## Ethical Publication Statement

We confirm that we have read the Journal's position on issues involved in ethical publication and affirm that this report is consistent with those guidelines.

## Conflicts of Interest

MP received speaker honoraria from Roche, Genzyme and Novartis, and travel/accommodation/meeting expenses from Novartis, Biogen Idec, Genzyme, and MERCK Serono. MB received meeting/accommodation expenses from Zambon and Shire. FK received meeting/accommodation expenses from Teva and Bayer. OB reports no conflicts of interests. JF reports no conflicts of interest. JM has received grants from Deutsche Forschungsgemeinschaft, Bundesministerium für Bildung und Forschung (BMBF), Else Kröner-Fresenius-Stiftung, EVER Pharma Jena GmbH, Ferrer International, travel grants from Boehringer Ingelheim and speaking fees from Bayer Vital. SGM receives honoraria for lecturing, and travel expenses for attending meetings from Almirall, Amicus Therapeutics Germany, Bayer Health Care, Biogen, Celgene, Diamed, Genzyme, MedDay Pharmaceuticals, Merck Serono, Novartis, Novo Nordisk, ONO Pharma, Roche, Sanofi-Aventis, Chugai Pharma, QuintilesIMS, and Teva. His research is funded by the German Ministry for Education and Research (BMBF), Deutsche Forschungsgesellschaft (DFG), Else Kröner-Fresenius Foundation, German Academic Exchange Service, Hertie Foundation, Interdisciplinary Center for Clinical Studies (IZKF) Muenster, German Foundation Neurology and Almirall, Amicus Therapeutics Germany, Biogen, Diamed, Fresenius Medical Care, Genzyme, Merck Serono, Novartis, ONO Pharma, Roche, and Teva. JN reports no conflicts of interest.

## Contributorship Statement

MP, MB, and JN have access to all the data and take responsibility for the data, accuracy of the data analysis and interpretation of the data, and drafting the manuscript for intellectual content. FK, JF, OB, JM, and SGM involved in design and conceptualization of the case and revising the manuscript for intellectual content.

## References

- Greenan TJ, Grossman RI, Goldberg HI. Cerebral vasculitis: MR imaging and angiographic correlation. *Radiology* 1992;182:65–72.
- Salvarani C, Brown RD, Calamia KT, et al. Primary central nervous system vasculitis: analysis of 101 patients. *Ann Neurol* 2007;62:442–451.
- Varhaug KN, Barro C, Bjørnevik K, et al. Neurofilament light chain predicts disease activity in relapsing-remitting MS. *Neurol Neuroimmunol Neuroinflamm* 2018;5:e422.
- Abdelhak A, Junker A, Brettschneider J, et al. Brain-specific cytoskeletal damage markers in cerebrospinal fluid: is there a common pattern between amyotrophic lateral sclerosis and primary progressive multiple sclerosis? *Int J Mol Sci* 2015;16:17565–17588.
- Constantinescu R, Krýsl D, Bergquist F, et al. Cerebrospinal fluid markers of neuronal and glial cell damage to monitor disease activity and predict long-term outcome in patients with autoimmune encephalitis. *Eur J Neurol* 2016;23:796–806.
- de Marchis GM, Katan M, Barro C, et al. Serum neurofilament light chain in patients with acute cerebrovascular events. *Eur J Neurol* 2018;25:562–568.
- Berlit P, Kraemer M. Cerebral vasculitis in adults: what are the steps in order to establish the diagnosis? Red flags and pitfalls. *Clin Exp Immunol* 2014;175:419–424.
- Becker J, Horn PA, Keyvani K, et al. Primary central nervous system vasculitis and its mimicking diseases - clinical features, outcome, comorbidities and diagnostic results - A case control study. *Clin Neurol Neurosurg* 2017;156:48–54.
- Vera-Lastra O, Sepúlveda-Delgado J, Cruz-Domínguez MdP, et al. Primary and secondary central nervous system vasculitis: clinical manifestations, laboratory findings, neuroimaging, and treatment analysis. *Clin Rheumatol* 2015;34:729–738.
- Hjalmarsson C, Bjerke M, Andersson B, et al. Neuronal and glia-related biomarkers in cerebrospinal fluid of patients with acute ischemic stroke. *J Cent Nerv Syst Dis* 2014;6:51–58.
- Pawlitzki M, Schreiber S, Bittner D, et al. CSF neurofilament light chain levels in primary progressive MS: signs of axonal neurodegeneration. *Front Neurol* 2018;9:1597.

## Supporting Information

Additional supporting information may be found online in the Supporting Information section at the end of the article.

**Supplemental Text 1:** Serological and cerebrospinal fluid diagnostics. \* indicates repeated Measurements.